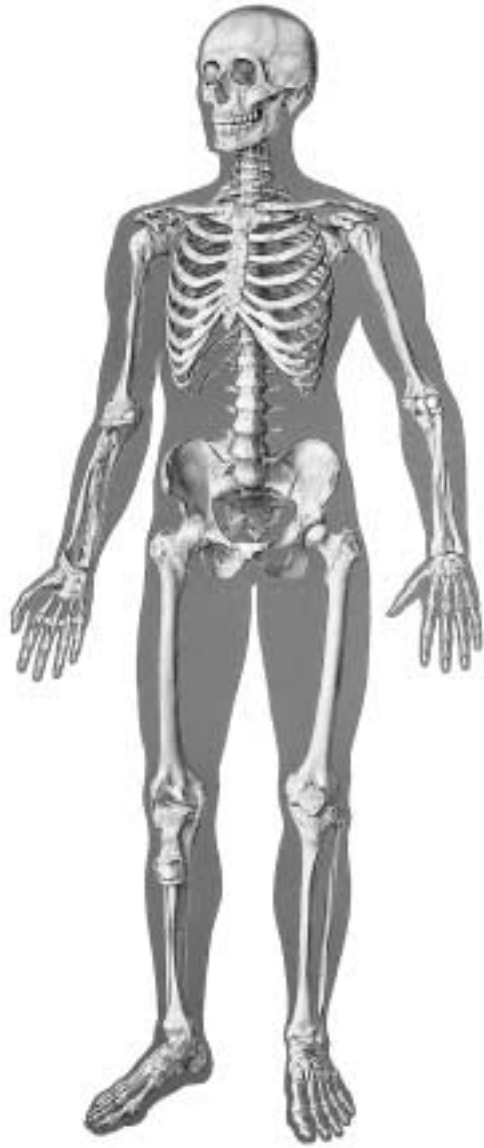

# V2001



|     |  |       |  |
|-----|--|-------|--|
| 1   | Os frontale                                | 36    | Os pubis                               |
| 2   | Os parietale                               | 37    | Os ischii                              |
| 3   | Os temporale                               | 38    | Os sacrum                              |
| 4   | Os zygomaticum                             | 39    | Os coccygis (Vertebrae coccygeae I-IV) |
| 5   | Processus mastoideus                       | 40    | Femur                                  |
| 6   | Mandibula                                  | 41    | Patella                                |
| 7   | Os nasale                                  | 42    | Tibia                                  |
| 8   | Orbita                                     | 43    | Fibula                                 |
| 9   | Maxilla                                    | 44    | Malleolus lateralis                    |
| 10  | Vertebra prominens                         | 45    | Malleolus medialis                     |
| 11  | Vertebra thoracica I                       | 46    | Ossa tarsi                             |
| 12  | Costae verae (I-VII)                       | 46a   | Talus                                  |
| 13  | Costae spuriae (VIII-XII)                  | 46b   | Os naviculare                          |
| 14  | Costa fluctuantes (XI+XII)                 | 46c   | Calcaneus                              |
| 15  | Clavicula                                  | 46d   | Os cuneiforme I-III                    |
| 16  | Acromion                                   | 46e   | Os cuboideum                           |
| 17  | Scapula                                    | 47    | Os metatarsale                         |
| 18  | Sternum, manubrium                         | 48    | Ossa digitorum (pedis)                 |
| 19  | Sternum, corpus                            | I     | Lig. coracoacromiale                   |
| 20  | Sternum, processus xiphoideus              | II    | Vagina tendinis intertubercularis      |
| 21  | Humerus                                    | III   | M. biceps brachii, caput longum, tendo |
| 22  | Humerus, caput                             | IV    | Articulatio, capsula                   |
| 23  | Humerus, epicondylus medialis              | V     | Lig. collaterale radiale               |
| 24  | Humerus, epicondylus lateralis             | VI    | Recessus sacciformis                   |
| 25  | Humerus, capitulum                         | VII   | Lig. collaterale ulnare                |
| 26  | Humerus, trochlea                          | VIII  | Lig. radiocarpale palmare              |
| 27  | Radius, caput                              | IX    | Lig. Collaterale                       |
| 28  | Radius                                     | X     | Lig. longitudinale anterius            |
| 29  | Ulna                                       | XI    | Lig. iliolumbale                       |
| 30  | Ossa carpi (Ossa carpalia)                 | XII   | Lig. iliofemorale                      |
| 30a | Os scaphoideum                             | XIII  | Lig. pubofemorale                      |
| 30b | Os lunatum                                 | XIV   | Lig. collaterale fibulare              |
| 30c | Os triquetrum                              | XV    | Lig. transversum genus                 |
| 30d | Os pisiforme                               | XVI   | Meniscus medialis                      |
| 30e | Os trapezium                               | XVII  | Lig. patellae                          |
| 30f | Os trapezoideum                            | XVIII | Lig. collaterale tibiale               |
| 30g | Os capitatum                               | XIX   | Lig. Deltoideum                        |
| 30h | Os hamatum                                 |       |  |
| 31  | Ossa metacarpalia                          |       |  |
| 32  | Manus, ossa digitorum                      |       |  |
| 32a | Manus, phalanx proximalis                  |       |  |
| 32b | Manus, phalanx media                       |       |  |
| 32c | Manus, phalanx distalis                    |       |  |
| 33  | Vertebra lumbalis                          |       |  |
| 34  | Vertebra lumbalis I, processus transversus |       |  |
| 35  | Os ilium                                   |       |  |

|     |   |       |  |
|-----|---|-------|--|
| 1   | Frontal bone                                  | 35    | Iliac bone                                   |
| 2   | Parietal bone                                 | 36    | Pubic bone                                   |
| 3   | Temporal bone                                 | 37    | Ischial bone                                 |
| 4   | Zygomatic bone (cheekbone)                    | 38    | Sacral bone                                  |
| 5   | Mastoid process                               | 39    | Coccygeal bone                               |
| 6   | Mandibula (mandible)                          | 40    | Femur (thigh bone)                           |
| 7   | Nasal bone                                    | 41    | Patella                                      |
| 8   | Orbital cavity                                | 42    | Tibia (shin bone)                            |
| 9   | Maxillary bone                                | 43    | Fibula                                       |
| 10  | Prominent vertebra                            | 44    | Lateral malleolus                            |
| 11  | 1st thoracic vertebra                         | 45    | Medial malleolus                             |
| 12  | True ribs (I-VII)                             | 46    | Tarsal bone                                  |
| 13  | False ribs (VIII-XII)                         | 46a   | Talus  |
| 14  | Floating ribs (XI+XII)                        | 46b   | Navicular bone                               |
| 15  | Clavicle                                      | 46c   | Calcaneus (heel bone)                        |
| 16  | Acromion (acromial bone)                      | 46d   | Cuneiform bone I-III                         |
| 17  | Scapula                                       | 46e   | Cuboid bone                                  |
| 18  | Manubrium of sternum                          | 47    | Metatarsal bone                              |
| 19  | Sternal body                                  | 48    | Bones of the toes                            |
| 20  | Xiphoid process                               | I     | Coracoacromial ligament                      |
| 21  | Head of humerus                               | II    | Intertubercular synovial sheath              |
| 22  | Humerus                                       | III   | Tendon of long head of biceps brachii muscle |
| 23  | Medial epicondyle of humerus                  |       |  |
| 24  | Lateral epicondyle of humerus                 | IV    | Articular, capsule                           |
| 25  | Radial head of humerus (capitulum of humerus) | V     | Radial collateral ligament                   |
| 26  | Trochlea of humerus                           | VI    | Sacciform recess                             |
| 27  | Head of radius                                | VII   | Ulnar collateral ligament                    |
| 28  | Radius (radial bone)                          | VIII  | Palmar radiocarpal ligament                  |
| 29  | Ulna  | IX    | Collateral ligament                          |
| 30  | Carpal bones                                  | X     | Anterior longitudinal ligament               |
| 30a | Scaphoid bone                                 | XI    | Iliolumbar ligament                          |
| 30b | Lunate bone                                   | XII   | Iliofemoral ligament                         |
| 30c | Triquetral bone                               | XIII  | Pubofemoral ligament                         |
| 30d | Pisiform bone                                 | XIV   | Fibular collateral ligament                  |
| 30e | Trapezium bone                                | XV    | Transverse ligament of knee                  |
| 30f | Trapezoid bone                                | XVI   | Medial meniscus of knee                      |
| 30g | Capitate bone                                 | XVII  | Patellar ligament                            |
| 30h | Hamate bone                                   | XVIII | Tibial collateral ligament                   |
| 31  | Metacarpal bones                              | XIX   | Deltoid ligament of ankle                    |
| 32  | Digital bones of hand                         |       |  |
| 32a | Proximal phalanx of hand                      |       |  |
| 32b | Medial phalanx of hand                        |       |  |
| 32c | Distal phalanx of hand                        |       |  |
| 33  | Lumbar vertebra                               |       |  |
| 34  | Transverse process of 1st lumbar vertebra     |       |  |

# Das Skelett des Menschen mit Bandapparat

Deutsch

Español

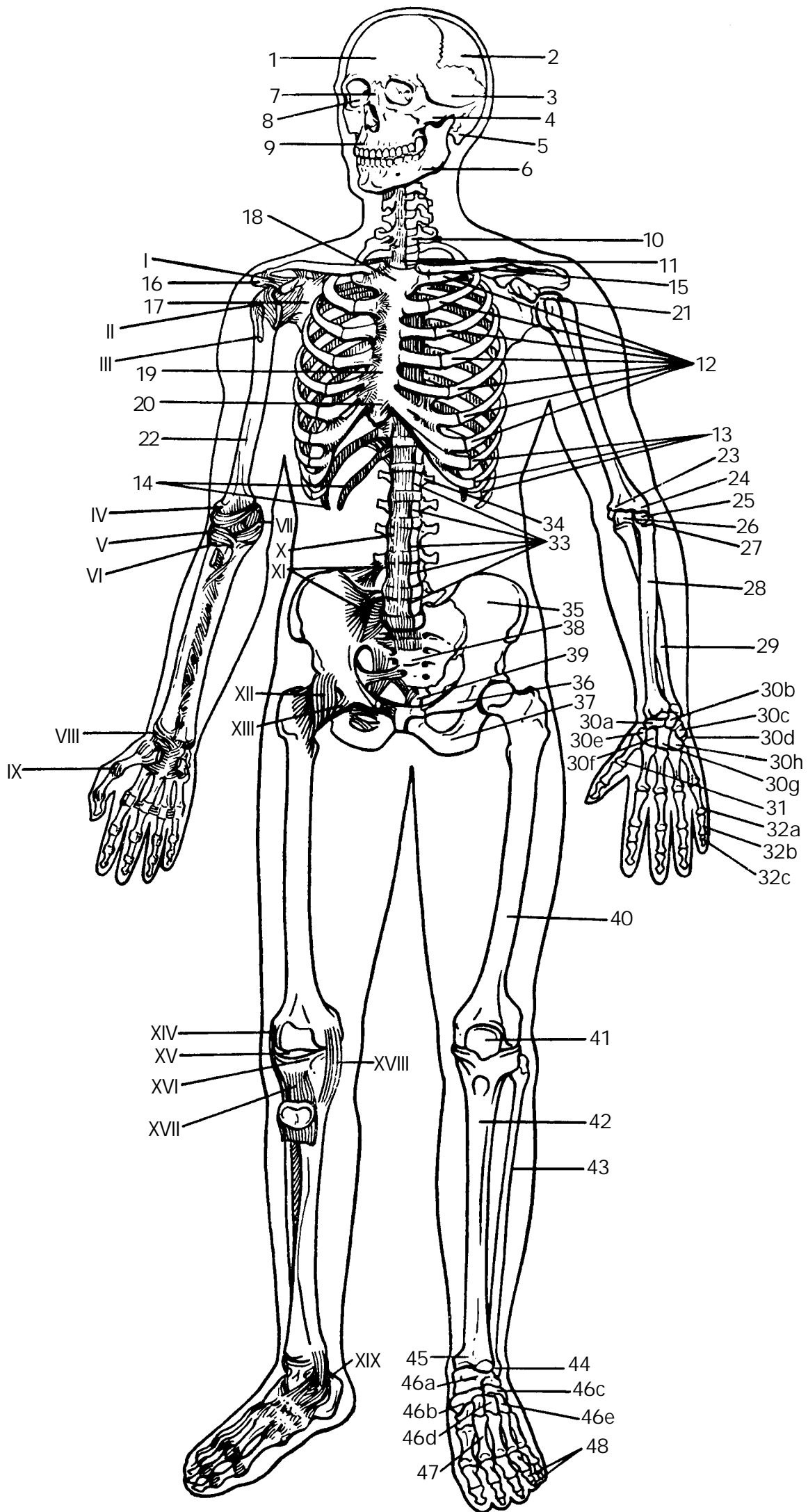
# El Esqueleto Humano con ligamentos

Frontal

Vorderseite

|     |   |       |  |
|-----|---|-------|--|
| 1   | Stirnbein   | 33    | Lendenwirbel                           |
| 2   | Scheitelbein  | 34    | 1. Lendenwirbel, Querfortsatz          |
| 3   | Schläfenbein  | 35    | Darmbein                               |
| 4   | Jochbein  | 36    | Schambein                              |
| 5   | Warzenfortsatz  | 37    | Sitzbein                               |
| 6   | Unterkiefer   | 38    | Kreuzbein                              |
| 7   | Nasenbein   | 39    | Steißbein                              |
| 8   | Augenhöhle  | 40    | Oberschenkelknochen                    |
| 9   | Oberkiefer  | 41    | Kniescheibe                            |
| 10  | Hervorstehender Wirbel (7. Halswirbel)                              | 42    | Schienbein                             |
| 11  | 1. Brustwirbel  | 43    | Wadenbein                              |
| 12  | Mit dem Brustbein unmittelbar in Verbindung tretende Rippen (I-VII) | 44    | Außenknöchel                           |
| 13  | Rippen ohne direkte Verbindung zum Brustbein (VIII-XII)             | 45    | Innenknöchel                           |
| 14  | Frei in der Bauchwand endigende Rippen (XI+XII)                     | 46    | Fußwurzelknochen                       |
| 15  | Schüsselbein  | 46a   | Sprungbein                             |
| 16  | Schulterhöhe  | 46b   | Kahnbein                               |
| 17  | Schulterblatt   | 46c   | Fersenbein                             |
| 18  | Handgriff des Brustbeins  | 46d   | Keilbein I-III                         |
| 19  | Brustbeinkörper   | 46e   | Würfelbein                             |
| 20  | Schwertfortsatz   | 47    | Mittelfußknochen                       |
| 21  | Oberarmkopf   | 48    | Zehenknochen                           |
| 22  | Oberarmknochen  | I     | Lig. coracoacromiale                   |
| 23  | Innerer Ellenbogenhöcker  | II    | Vagina tendinis intertubercularis      |
| 24  | Äußerer Ellenbogenhöcker  | III   | M. biceps brachii, caput longum, tendo |
| 25  | Oberarmköpfchen   | IV    | Gelenkkapsel                           |
| 26  | Walze des Oberarmknochens   | V     | Außenband                              |
| 27  | Speichenkopf  | VI    | Recessus sacciformis                   |
| 28  | Speiche   | VII   | Innenband                              |
| 29  | Elle  | VIII  | Lig. radiocarpale palmare              |
| 30  | Handwurzelknochen   | IX    | Lig. Collaterale                       |
| 30a | Kahnbein  | X     | Vorderes Längsband                     |
| 30b | Mondbein  | XI    | Lig. iliolumbale                       |
| 30c | Dreiecksbein  | XII   | Darmbein-Oberschenkelband              |
| 30d | Erbsenbein  | XIII  | Schambein-Oberschenkelband             |
| 30e | Großes Vieleckbein  | XIV   | Äußeres Seitenband (Kniegelenk)        |
| 30f | Kleines Vieleckbein   | XV    | Lig. transversum genus                 |
| 30g | Kopfbein  | XVI   | Innenmeniskus                          |
| 30h | Hakenbein   | XVII  | Kniescheibenband                       |
| 31  | Mittelhandknochen   | XVIII | Inneres Seitenband (Kniegelenk)        |
| 32  | Fingerknochen   | XIX   | Lig. Deltoideum                        |
| 32a | Fingergrundglied  |       |  |
| 32b | Fingermittelglied   |       |  |
| 32c | Fingerendglied  |       |  |

|     |   |       |  |
|-----|---|-------|--|
| 1   | Hueso frontal                           | 36    | Hueso pubis                              |
| 2   | Hueso parietal                          | 37    | Hueso isquion                            |
| 3   | Hueso temporal                          | 38    | Hueso sacro                              |
| 4   | Hueso cigomático                        | 39    | Hueso coccígeo (vétrebras coccígeas)     |
| 5   | Apófisis mastoides                      | 40    | Fémur                                    |
| 6   | Mandíbula                               | 41    | Rótula                                   |
| 7   | Hueso nasal                             | 42    | Tibia                                    |
| 8   | Órbita                                  | 43    | Peroné                                   |
| 9   | Maxilar                                 | 44    | Maléolo lateral                          |
| 10  | Vértebra prominente                     | 45    | Maléolo medial                           |
| 11  | I vértebra torácica                     | 46    | Hueso del tarso                          |
| 12  | Costillas verdaderas (I-II)             | 46a   | Astrágalo                                |
| 13  | Costillas falsas (VIII-XII)             | 46b   | Escafoides                               |
| 14  | Costillas flotantes (XI+XII)            | 46c   | Calcáneo                                 |
| 15  | Clavícula                               | 46d   | Cuña I-III                               |
| 16  | Acromion                                | 46e   | Hueso cuboides                           |
| 17  | Escápula                                | 47    | Metatarsiamo                             |
| 18  | Esternón, manubrio                      | 48    | Falanges del pie                         |
| 19  | Esternón, cuerpo                        | I     | Lig. coracoacromial                      |
| 20  | Apófisis xifoideas                      | II    | Vaina tendinosa intertubercular          |
| 21  | Húmero, cabeza                          | III   | M. bíceps braquial, cabeza larga, tendón |
| 22  | Húmero                                  | IV    | Articulación, capsula                    |
| 23  | Húmero, epicóndilo medial               | V     | Lig. colateral radial                    |
| 24  | Húmero, epicóndilo lateral              | VI    | Prolongación del cul-de-sac              |
| 25  | Húmero, cóndilo humeral                 | VII   | Lig. colateral cubital                   |
| 26  | Húmero, tróclea                         | VIII  | Lig. radiocarpiano palmar                |
| 27  | Radio, cabeza                           | IX    | Lig. Colateral                           |
| 28  | Radio                                   | X     | Lig. longitudinal anterior               |
| 29  | Cúbito                                  | XI    | Lig. iliolumbar                          |
| 30  | Huesos del carpo                        | XII   | Lig. iliofemoral                         |
| 30a | Hueso escafoides                        | XIII  | Lig. pubofemoral                         |
| 30b | Hueso semilunar                         | XIV   | Lig. colateral peroné                    |
| 30c | Hueso piramidal                         | XV    | Lig. transverso de la rodilla            |
| 30d | Hueso pisiforme                         | XVI   | Menisco medial                           |
| 30e | Hueso trapecio                          | XVII  | Lig. rotuliano                           |
| 30f | Hueso trapecoide                        | XVIII | Lig. colateral tibial                    |
| 30g | Hueso grande                            | XIX   | Lig. Deltoideo                           |
| 30h | Hueso ganchoso                          |       |  |
| 31  | Huesos metacarpianos I-IV               |       |  |
| 32  | Mano, huesos de los dedos               |       |  |
| 32a | Mano, flange proximal                   |       |  |
| 32b | Mano, falange media                     |       |  |
| 32c | Mano, falange distal                    |       |  |
| 33  | Vértebra lumbar                         |       |  |
| 34  | I vértebra lumbar, apófisis transversal |       |  |
| 35  | Hueso ilion                             |       |  |



# Le Squelette Humain avec ligaments

Français

Português

# O Esqueleto Humano com ligamentos

Vue Frontale

Frontal

|     |                                    |       |  |
|-----|------------------------------------|-------|--|
| 1   | Os frontal                         | 36    | Os pubien                                  |
| 2   | Os pariétal                        | 37    | Os ischiatique                             |
| 3   | Os temporal                        | 38    | Os sacrum                                  |
| 4   | Os zygomatique                     | 39    | Coccyx (vertèbres coccygiennes I-IV)       |
| 5   | Apophyse mastoïdienne              | 40    | Fémur                                      |
| 6   | Mandibule                          | 41    | Rotule                                     |
| 7   | Os nasal                           | 42    | Tibia                                      |
| 8   | Orbite                             | 43    | Péroné                                     |
| 9   | Maxillaire                         | 44    | Malléole latérale                          |
| 10  | Vertèbre proéminente               | 45    | Malléole médiale                           |
| 11  | Vertèbre thoracique I              | 46    | Os du tarse                                |
| 12  | Côtes vraies (I-VII)               | 46a   | Astragale                                  |
| 13  | Côtes fausses (VIII-XII)           | 46b   | Os naviculaire                             |
| 14  | Côtes flottantes (XI+XII)          | 46c   | Calcaneum                                  |
| 15  | Clavicule                          | 46d   | Os cunéiforme I-III                        |
| 16  | Acromion                           | 46e   | Os cuboïde du tarse                        |
| 17  | Epaule                             | 47    | Os métatarsien                             |
| 18  | Sternum, manche                    | 48    | Phalanges des orteils                      |
| 19  | Sternum, corps                     | I     | Ligament coraco-acromial                   |
| 20  | Pointe du sternum                  | II    | Gaine synoviale intertuberculaire          |
| 21  | Humérus, tête                      | III   | Muscle biceps du bras, tête longue, tendon |
| 22  | Humérus                            | IV    | Articulation, capsule                      |
| 23  | Humérus, épicondyle médial         | V     | Ligament radial collatéral                 |
| 24  | Humérus, épicondyle latéral        | VI    | Prolongement eu cul-de-sac                 |
| 25  | Humérus, petite tête               | VII   | Ligament latéral interne du coude          |
| 26  | Humérus, trochlée                  | VIII  | Ligament radiocarpien palmaire             |
| 27  | Radius, tête                       | IX    | Ligament collatéral                        |
| 28  | Radius                             | X     | Ligament longitudinal antérieur            |
| 29  | Cubitus                            | XI    | Ligament iliolumbaire                      |
| 30  | Os du carpe (os carpiens)          | XII   | Ligament iliofémoral                       |
| 30a | Os scaphoïde                       | XIII  | Ligament pubofémoral                       |
| 30b | Os lunaire                         | XIV   | Ligament péronier collatéral               |
| 30c | Os triquètre                       | XV    | Ligament transverse du genou               |
| 30d | Os pisiforme                       | XVI   | Ménisque interne                           |
| 30e | Os trapèze                         | XVII  | Ligament de la rotule                      |
| 30f | Os trapézoïde                      | XVIII | Ligament tibial collatéral                 |
| 30g | Grand os du carpe en forme de tête | XIX   | Ligament deltoïde                          |
| 30h | Os crochu                          |       |  |
| 31  | Os métacarpiens                    |       |  |
| 32  | Main, os des doigts                |       |  |
| 32a | Main, phalange proximale           |       |  |
| 32b | Main, phalange moyenne             |       |  |
| 32c | Main, phalange distale             |       |  |
| 33  | Vertèbre lombaire                  |       |  |
| 34  | Vertèbre lombaire I, apophyse      |       |  |
| 35  | Os iliaque                         |       |  |

|     |  |       |   |
|-----|--|-------|---|
| 1   | Osso frontal                               | 36    | Osso púbis  |
| 2   | Osso parietal                              | 37    | Ísqquo  |
| 3   | Osso temporal                              | 38    | Sacro   |
| 4   | Osso zigomático                            | 39    | Cóccix  |
| 5   | Processo mastóide                          | 40    | Fêmur   |
| 6   | Mandíbula                                  | 41    | Rótula (patela)   |
| 7   | Osso nasal                                 | 42    | Tíbia   |
| 8   | Órbita (cavidade orbitária)                | 43    | Fíbula (perônio)  |
| 9   | Maxilar                                    | 44    | Maléolo lateral (extramaléolo)                            |
| 10  | Vértebra proeminente                       | 45    | Pescoço do martelo (colo do martelo)                      |
| 11  | Primeira vértebra torácica                 | 46    | Ossos do tarso  |
| 12  | Costelas verdadeiras (I-VII)               | 46a   | Talo (osso do tornozelo)                                  |
| 13  | Costelas falsas (VIII-XII)                 | 46b   | Osso navicular (osso central do tornozelo)                |
| 14  | Costelas flutuantes (XI+XII)               | 46c   | Osso do calcânhar   |
| 15  | Clavicula                                  | 46d   | Osso cuneiforme I-III                                     |
| 16  | Acrômio (processo acromial)                | 46e   | Osso cubóide  |
| 17  | Escápula                                   | 47    | Osso do metatarso   |
| 18  | Manúbrio esternal (pré-esterno)            | 48    | Osso dos dedos (pes)                                      |
| 19  | Corpo do esterno (mesosterno)              | I     | Ligamento coracoacromial                                  |
| 20  | Cartilagem xifóidea                        | II    | Bainha tendínea intertubercular                           |
| 21  | Cabeça do úmero                            | III   | Tendão da cabeça longa do músculo biceps braquial         |
| 22  | Úmero                                      | IV    | Cápsula articular   |
| 23  | Epicôndilo medial do úmero                 | V     | Ligamento colateral radial                                |
| 24  | Epicôndilo lateral do úmero                | VI    | Rcesso saciforme  |
| 25  | Capítulo do úmero                          | VII   | Ligamento colateral ulnar                                 |
| 26  | Tróclea do úmero                           | VIII  | Ligamento radiocárpico palmar                             |
| 27  | Cabeça do rádio                            | IX    | Ligamento colateral                                       |
| 28  | Rádio                                      | X     | Ligamento longitudinal anterior                           |
| 29  | Ulna (cúbito)                              | XI    | Ligamento iliolumbar                                      |
| 30  | Ossos do carpo                             | XII   | Ligamento iliofemoral (ligamento de Bertin)               |
| 30a | Osso escafóide (osso navicular da mão)     | XIII  | Ligamento pubofemoral                                     |
| 30b | Osso semilunar                             | XIV   | Ligamento colateral fibular (ligamento lateral do joelho) |
| 30c | Osso piramidal                             | XV    | Ligamento transversal do joelho                           |
| 30d | Osso pisiforme                             | XVI   | Menisco medial  |
| 30e | Osso trapézio                              | XVII  | Ligamento patelar   |
| 30f | Osso trapezóide                            | XVIII | Ligamento colateral da tíbia                              |
| 30g | Osso capitato                              | XIX   | Ligamento deltoídeo                                       |
| 30h | Osso hamato                                |       |   |
| 31  | Ossos metacarpianos                        |       |   |
| 32  | Ossos dos dedos da mão                     |       |   |
| 32a | Flange proximais da mão                    |       |   |
| 32b | Falange média da mão                       |       |   |
| 32c | Falange distais da mão                     |       |   |
| 33  | Vértebra lombar                            |       |   |
| 34  | Processo transverso da 1a. Vertebra lombar |       |   |
| 35  | Osso ilíaco                                |       |   |

# 骨格と靭帯

## 前面

- |     |          |       |             |
|-----|----------|-------|-------------|
| 1   | 前頭骨      | 36    | 恥骨          |
| 2   | 頭頂骨      | 37    | 坐骨          |
| 3   | 側頭骨      | 38    | 仙骨          |
| 4   | 頬骨       | 39    | 尾骨          |
| 5   | 乳様突起     | 40    | 大腿骨         |
| 6   | 下顎骨      | 41    | 膝蓋骨         |
| 7   | 鼻骨       | 42    | 脛骨          |
| 8   | 眼窩腔      | 43    | 腓骨          |
| 9   | 上顎骨      | 44    | 外果          |
| 10  | 隆椎（第七頸椎） | 45    | 内果          |
| 11  | 第一胸椎     | 46    | 足根骨         |
| 12  | 真肋       | 46a   | 距骨          |
| 13  | 仮肋       | 46b   | 舟状骨         |
| 14  | 浮游弓肋     | 46c   | 踵骨          |
| 15  | 鎖骨       | 46d   | 楔状骨（I-III）  |
| 16  | 肩峰       | 46e   | 立方骨         |
| 17  | 肩甲骨      | 47    | 中足骨         |
| 18  | 胸骨柄      | 48    | 足跡の骨        |
| 19  | 胸骨体      | I     | 烏口肩峰靭帯      |
| 20  | 胸骨剣状突起   | II    | 結節間滑液鞘      |
| 21  | 上腕骨頭     | III   | 上腕二頭筋腱の長頭   |
| 22  | 上腕骨      | IV    | 関節包         |
| 23  | 上腕骨内側上顆  | V     | 外側側副靭帯      |
| 24  | 上腕骨外側上顆  | VI    | 橈骨輪状靭帯の囊状陥凹 |
| 25  | 上腕骨小頭    | VII   | 内側側副靭帯      |
| 26  | 上腕骨滑車    | VIII  | 掌側橈骨の靭帯     |
| 27  | 橈骨頭      | IX    | 側副靭帯        |
| 28  | 橈骨       | X     | 前縦靭帯        |
| 29  | 尺骨       | XI    | 腸腰靭帯        |
| 30  | 手根骨      | XII   | 腸骨大腿靭帯      |
| 30a | 舟状骨      | XIII  | 恥骨大腿靭帯      |
| 30b | 月状骨      | XIV   | 外側側副靭帯      |
| 30c | 三角骨      | XV    | 膝横靭帯        |
| 30d | 豆状骨      | XVI   | 内側半月        |
| 30e | 大菱形骨     | XVII  | 膝蓋靭帯        |
| 30f | 小菱形骨     | XVIII | 内側側副靭帯      |
| 30g | 有頭骨      | XIX   | 三角靭帯        |
| 30h | 有鈎骨      |       |             |
| 31  | 中手骨      |       |             |
| 32  | 手指の骨     |       |             |
| 32a | 手の基節骨    |       |             |
| 32b | 手の中節骨    |       |             |
| 32c | 手の末節骨    |       |             |
| 33  | 胸椎       |       |             |
| 34  | 第一腰椎横突起  |       |             |
| 35  | 腸骨       |       |             |



**3B Scientific Products**

Internet: <http://www.3bscientific.com>